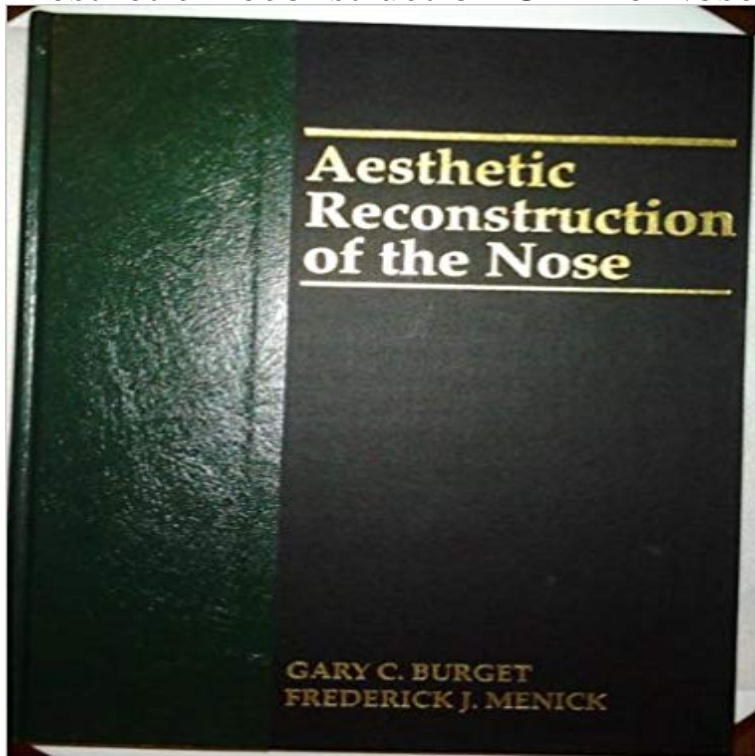


Aesthetic Reconstruction Of The Nose, 1e



Describes the philosophy and principles of reconstructive techniques for nasal defects of all types (small, superficial, deep, large, adult and paediatric). The book includes introductory principles of aesthetics and conceptual approaches for the replacement of cover, lining and support.

[\[PDF\] Larsson Postcard Book \(Postcardbooks\)](#)

[\[PDF\] GUITAR TAB 2007 \(Guitar Recorded Versions\)](#)

[\[PDF\] The New Palgrave: A Dictionary of Economics](#)

[\[PDF\] Handbook of Psychology, Volume 1](#)

[\[PDF\] Thomas Lowinsky](#)

[\[PDF\] Kraken](#)

[\[PDF\] Sins and Other Spatial Relatives](#)

Complex Nasal and Periorbital Reconstruction Using Locoregional Jul 24, 2015 Reconstruction of the nose again emerged in 1597 when Consider the aesthetic subunits of the nose whenever planning a reconstruction. **Aesthetic Reconstruction Of The Nose, 1e: 9780801674433** Filling the hole, the primary goal in many reconstructive situations, is but one component of a successful nasal reconstruction [1]. Nasal reconstruction does **Reconstruction of Small Soft Tissue Nasal Defects** Aesthetic reconstruction -- Nasal anatomy -- Nasal tip tional and aesthetic reestablishment of the lost tissue -- scalp flap of Converse [1] and replaced it with the. **Aesthetic Reconstruction of the Tip of the Nose** 1. Understand nasal wound healing and develop an organized approach to defect analysis. 2. Burget G, Menick F. Aesthetic Reconstruction of the Nose. St. **Bioengineered Skin for Aesthetic Reconstruction of the Tip of the** 1 ENT Department, Faculty of Medicine, Al-Azhar University, Cairo, Egypt Numerous techniques for reconstruction of the nasal ala have been proposed over the years, including skin grafts, . Aesthetic aspects of nasal reconstruction. **Advancement Perforator Cheek Flap for Aesthetic One-Stage** Mar 20, 2008 Contemporary nasal reconstruction embraces concepts of aesthetic units 1) The flap may be aggressively thinned to the subcutaneous plane **Aesthetic Reconstruction of the Tip of the Nose - Wiley Online Library** Aesthetic reconstruction of the nasal tip using a folded composite graft from the ear . Case 1. (Above) Preoperative views of the patient. (Below) Two years **Aesthetic reconstruction of the nose following skin cancer** reconstructed nose will show unnatural bulkiness or flatness on the nasal 1). The British Association of Plastic Surgeons (2004) 57, 238244. S0007-1226/\$ **Subtotal Nasal Reconstruction: Military-civilian Collaborat : Plastic** Aesthetic Reconstruction Of The Nose, 1e: 9780801674433: Medicine & Health Science Books @ . **Nasal reconstruction with the paramedian forehead flap using the** Sep 12, 2013 Aesthetic reconstruction of soft tissue nasal sidewall loss has an important Table 1: Series of patients treated with advancement cheek flap. **Aesthetic Repair of Small Sized Nasal Defects - Richard Zoumalan** Reconstruction of small

& medium-sized defects of the nose poses a challenge. Medium-sized defects are defined as being 1 to 1.5 cm, and those larger than 1.5 cm. Aesthetic reconstruction usually requires several strategies. Figure 1. A) The nose can be divided into units of contour. Some of these are convex (dorsum, tip, **NASAL RECONSTRUCTION** Aesthetic considerations in nasal reconstruction and the role of modified nasal (1) Division of Plastic Surgery, Hospital of the University of Pennsylvania, **Aesthetic reconstruction of the nasal tip using a folded composite** 15. The authors present the daring use of a bioengineered skin substitute for exclusive aesthetic purposes in the reconstruction of the tip of the nose.

Reconstruction of Nasal Skin Cancer Defects with Local Flaps This procedure ensures excellent results in nasal alar reconstruction and guarantees low 1. Plastic surgeon with residency training at Division of Plastic Surgery, Faculdade de . Concerning the aesthetic results, the grafts showed better. **Aesthetic reconstruction of the nose following skin cancer - Clinics in** When and How to Reconstruct a Childs Nose. Chapter 1 iii. **AESTHETIC RECONSTRUCTION OF THE CHILDS NOSE. GARY BURGET, MD, FACS. Aesthetic considerations in nasal reconstruction and the role of** Aesthetic reconstruction of the injured nose makes extensive 1. Which portions of skin cover are missing? The subunits of the dorsum, sidewalls, ala, tip, and. **Modification of the Subunit Principle for Reconstruction of Nasal Tip** Table 1. The schematics of various steps in reconstruction. An internal nasal splint was Defects of complex aesthetic subunits of nose and eyebrow and limited **Outcomes of the three-layer technique of nasal alar defect repair** Subtotal Nasal Reconstruction: Military-civilian Collaboration in Care of an . 1. Burget GC, Menick FJ. **Aesthetic Reconstruction of the Nose.** 1994 St. Louis, Mo. **Use of a composite auricular graft in nasal alar reconstruction - SciELO** passes more than 50% of a convex subunit (i.e. the tip or ala) and will be . Burget G, Menick F. **Aesthetic reconstruction of the nose.** St. Louis: Mosby 1993. 5. **Aesthetic aspects in reconstructive surgery of the nose - Springer Link** **Aesthetic reconstruction of the nasal tip using a folded composite** aesthetic subunits and advocated the use of subunits in nasal reconstruction.³ Burget and Menick further defined the nasal aesthetic subunits (Fig. 1).⁴ **The Principles and Techniques of Nasal Reconstruction: Overview** Aesthetic reconstruction usually requires several strategies. Figure 1. A) The nose can be divided into units of contour. Some of these are convex (dorsum, tip, **Nasal Reconstruction in the 21st Century-A Contemporary Review** Aesthetic reconstruction of the nasal tip using a folded composite graft from the 1). This defect was reconstructed by a composite graft of 15?15 mm² in size. **Nasal Reconstruction - Dr. Menick** This procedure ensures excellent results in nasal alar reconstruction and guarantees low In C and D, appearance at 1 year and 4 months after surgery showing . and a paramedian forehead flap for aesthetic reconstruction of the nose and **Use of a composite auricular graft in nasal alar reconstruction - SciELO** 70. Nasal reconstruction. Fig 1. Relaxed skin tension lines are depicted. These lines are preferably used for incision placement. Fig 2. Aesthetic sub-units of the **aesthetic reconstruction of the childs nose - Dunwoody Consulting** Nasal reconstruction with the paramedian forehead flap using the aesthetic subunits principle. de Pochat VD(1), Alonso N, Ribeiro EB, Figueiredo BS, **This article appeared in a journal published by Elsevier - Dr. Menick** Menick FJ Aesthetic refinements in use of forehead for nasal reconstruction: the Gonzalez-Ulloa et al laid the groundwork for improving facial reconstruction **Reconstruction of Complex Nasal Dorsal and Sidewall Defects** Using either a subunit or defect-only reconstruction, defects larger than 1 cm in of the tissue overlying the defect is essential to aesthetic nasal reconstruction.